

THE EFFECT OF LOW LEVEL LASER THERAPY ON SURGICAL WOUND HEALING

MIHAELA ANTONINA CALIN¹, TOMA COMAN², MARIAN ROMEO CALIN³

¹National Institute of Research and Development for Optoelectronics – INOE 2000,
409 Atomistilor str., PO BOX MG5, 077125, Magurele, Ilfov, Romania, Phone/fax: +40214574522,
E-mail: micalin@inoe.inoe.ro, antoninacalin@yahoo.com

²Veterinary Medicine Faculty, Spiru Haret University, Bucharest, Romania,
Phone/fax: +40212421575, E-mail: comantoma@yahoo.com

³“Horia Hulubei” National Institute of Physics and Nuclear Engineering - IFIN HH,
407 Atomistilor Street, P.O. Box MG-6, 077125, Magurele, Ilfov, Romania, Phone: +(4021)
404.23.00, Fax: +(4021) 4046199

(Received May 25, 2010)

Abstract: Surgical wounds are superficial or deep wounds on skin or mucous membranes due to a surgical intervention using a scalpel to cut through skin or mucosa and the underlying tissue. The wound treatment costs in terms of finance and time are relatively high; the complete wound healing lasts 3 weeks. To reduce this period of healing of surgical wound and avoid complications, therapeutic methods and drug are used in postoperative period. One of these methods is Low Level Laser Therapy. This method has been used for treatment of wounds for over two decades in many medical facilities of the world. However, despite such wide clinical usage, there is still controversy regarding the efficacy of Low Level Laser Therapy in the treatment of wounds. Many laser systems, different laser parameters and irradiation conditions, and a great variety of treatment protocols lead to these conclusions. The goal of this paper is to present our evaluation of Low Level Laser Therapy role in surgical aseptic wound management based on the haematological examination, histological examination and biochemical blood analysis in rabbits using our laser system SCL-TR (INOE 2000).

Key words: wound, laser therapy, haematological examination, histological examination, biochemical blood analysis.

1. INTRODUCTION

Surgical wounds are superficial or deep wounds on skin or mucous membranes due to a surgical intervention using a scalpel to cut through skin or mucosa and the underlying tissue. These wounds have neat edges and can be easily approximated spontaneously or with Mio sutures [1].

Simple surgical wounds heal through a series of morphological changes called „sanatio per primam intentionem” [2]. During this process the inflammatory phenomena are moderate. The first step consists in the accumulation of a serous

exsudates as a result of plasma leakage, exsudates that coagulates into a fibrin net, the template for granulation tissue. The epidermis, through basal cell proliferation covers the superficial defect slowly and forms the epidermic scar. The dermic scar, formed by the granulation tissue is the result of a stimulation of fibrogenesis by adult connective cells which turn themselves into fibroblasts replacing the fibrocytes.

The granulation tissue forms through multiple mechanisms: enhancement of fibroblast proliferation, of collagen and elastine synthesis which forms the extracellular network of connective tissue, new synthesis of chemotactic factors and beta interferon by the fibroblasts. The glycose-amino-glycans formed by fibroblasts also form the fundamental substance of the connective tissue in the dermal scar. The abundant extracellular matrix gives more plasticity to the new tissue and permits nutrient diffusion. The whole area is infiltrated with macrophages and leucocytes, cells that speed the process of connective tissue regeneration.

Miofibroblasts are the result of fibroblast differentiation and have the role of getting together the edges of the wound through cell contraction. A very important role carry the blood vessels which are rapidly regenerated under the influence of angiogenetic factors secreted by fibroblasts, thus bringing nutrients and oxygen in the area. The vascular nets are stimulated by the nitric oxide and the local raising of calcium ions concentration in smooth muscle fibers from vessels walls, as a result of increasing activity from the mitochondrial ATP.

Endothelial cells from the vessel wall take part in the process of primary healing and synthesize multiplication factors for the fibroblasts and prostaglandins. Primary healing is a process lasting 8-12 days. At the completion of this process the sutures can be removed, but the wound is not yet fully healed. The complete healing lasts 3 weeks. To minimize the period of healing of the surgical wound and suppress some secondary effects, therapeutic methods and drug are used in post-operative process. One of these methods is Low Level Laser Therapy (LLLT).

LLLT has been used as treatment of wounds for over two decades in the many medical centers of the world [3-7]. However, despite such wide clinical usage, there is still controversy regarding the efficacy of LLLT in treatment of wounds [8-10]. Many laser systems (He-Ne, AlGaAs, InGaAlP, etc) [11-14], different laser parameters (wavelength, power, energy, pulse frequency, pulse duration, etc) [15, 16] and irradiation conditions (exposure time, frequency and duration of treatment) [17,1 8] and a great variety of treatment protocols lead to these conclusions [19]. The goal of this paper is to present our evaluation of LLLT role in surgical aseptic wound based on the haematological examination, histological examination and biochemical blood analysis using our laser system SCL-TR (INOE 2000, Bucharest, Romania).

2. MATERIALS AND METHODS

2.1. ANIMALS

Twenty clinical healthy rabbits (Big Belgian Hare strain) weighting more than 2 kg were used in this study. The animals were maintained in conditions stipulated by the Law 305/2006 referring to European Agreement for protection of animals used in experiments and other scientific purpose (1986) and by the Convention Protocol amend (Strasbourg 1998); Romania adopted this Law in 15th of February 2006.

The animals have been divided in 2 groups: experimental group (10 rabbits) and control group (10 rabbits). Animals were prepared for surgery by shaving the hair along the white line of the abdomen, were tranquilized with inhalator chloroform and the surgical site prepped with 10% beta dine solution. An incision was carried down through skin, subcutaneous tissue and underlying muscle on a distance of 8 cm. After the incision the wound was approximated with surgical silk interrupted suture.

2.2. LOW LEVEL LASER THERAPY

After 1 hour from surgery, the animals from the first group were irradiated with laser radiation at $\lambda = 635$ nm, $P = 15$ mW, $t_{exp} = 180$ s. The laser probe was situated 1 cm above the wound. The treatment procedure has been applied 7 days consecutively. No animal received any medication before or after surgery.

2.3. EVALUATION METHODS

The efficacy of LLLT has been evaluated by: haematological examination, histological examination and, biochemical blood analyses.

Haematological examination was carried out with a Coulter device using blood samples individually harvested from the 20 animals taking part in the experiment. The following data were collected: red blood cell count (RBC), white blood cell count, platelets count, average red blood cell volume (VEM), haemoglobine concentration (Hb), hematocrite (Ht), average red cell haemoglobine (HEM). The leukocytes distribution and the morphological changes of the blood cells were done with May Grumwald Giemsa coloured smears.

Histological examination – at the end of the irradiation period, biopsies were taken. The tissue was fixated in histological (formaldehyde neutral saline and Bouin) and histochemical (alcohol 80° and Carnoy) fixation substances. Tissue fragments were included in paraffine and cut at 6 µm. The following colorations were used: typical hematoxiline-eosine and trichromic Mallory, May Grunwald giemsa on a smear, cold giemsa, orceine for elastine fibers, Gomory for reticuline fibers.

Biochemical blood examination was done on serum samples with Refrovet device, the following data being gathered: serum glucose, blood urea, alkaline phosphatase, ALAT, ASAT, and Gamma glutaminyl transpherase.

2.4. STATISTICAL ANALYSIS

Data are presented as means \pm SD. The mean value and its standard deviation were calculated using Microsoft Excel.

3. RESULTS AND DISCUSSION

Clinical examinations showed differences between the 2 groups of animals starting the third postoperative day, when experimental group (laser irradiated animals) had a perfect wound edges approximation, with partial epitheliazation and no serous or bloody exsudates. Epidermic crusts protect the development of dermal scars. The inflammation has been low and in the 6th day the sutures can be removed. The healing process is over in ten days.

In the control group the healing process was slow. In the 7th postoperative day, the wounds were not healed and the sutures were not ready to be removed. Primary healing was delayed. In the 10th postoperative day the wound was not fully epithelized. The histological examination on fragments of tissue harvested at 7 days laser therapy has shown a complete forming of the dermic scar and reepitheliazation of the wound (Fig. 1a).

In the deep dermis we can see scar connective tissue made of young collagen and lacking hair follicles. In the papillary dermis the nets of elastine and reticulin fibers are regeneration, the fibroblasts being situated in the papillary dermis, under the basal membrane. In the deep dermis the skin muscle is replaced by scarred connective tissue (Fig. 1b) and blood and lymphatic vessels are formed, increasing the circulation of blood and the lymphatic drainage (Fig. 1c). The predominating cells are macrophages, lymphocytes and fibroblasts. The newly formed collagen is highly acidophilic.

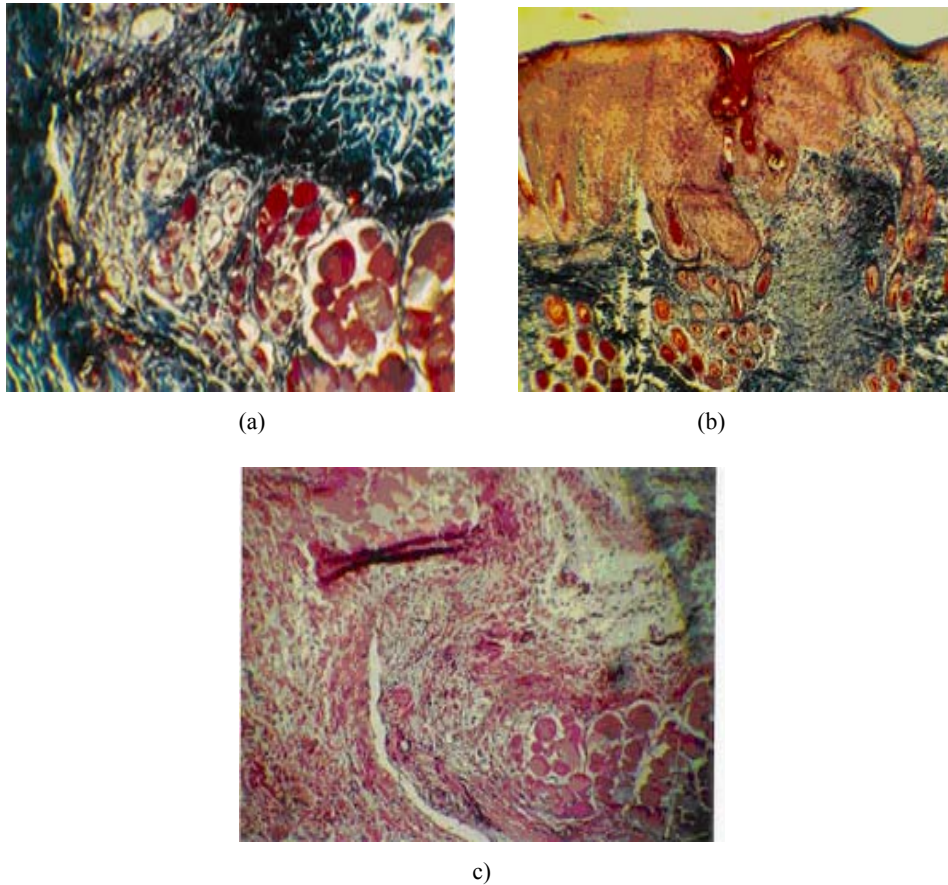


Fig. 1 – Experimental group (animal 1) surgical wound in the 7th laser therapy day; a) papillary dermis (trichromic coloration 4 ×); b) the zone of the skin muscle (trichromic coloration, 20 ×); c) blood and lymphatic vessels (HE coloration, 10 ×).

The control group shows slower healing processes. The epithelization is blocked by the local inflammatory process. In the papillary dermis the necrosis is seen even after 7 days (Fig. 2a).

The dermis shows infiltration with macrophages, lymphocytes and neutrophils. In the epidermis the hyperkeratosis is the main process (Fig. 2b). In the papillary dermis we found oedema, inflammatory cells infiltration and fibroblastic infiltration. The dermal scar is in the organizing stage, with young connective tissue cells and allogenic cells (lymphocytes, monocytes and plasmocytes). In the region we can also find scar tissue with forming vascular network, the epithelization process being not yet finished (Fig. 2c).

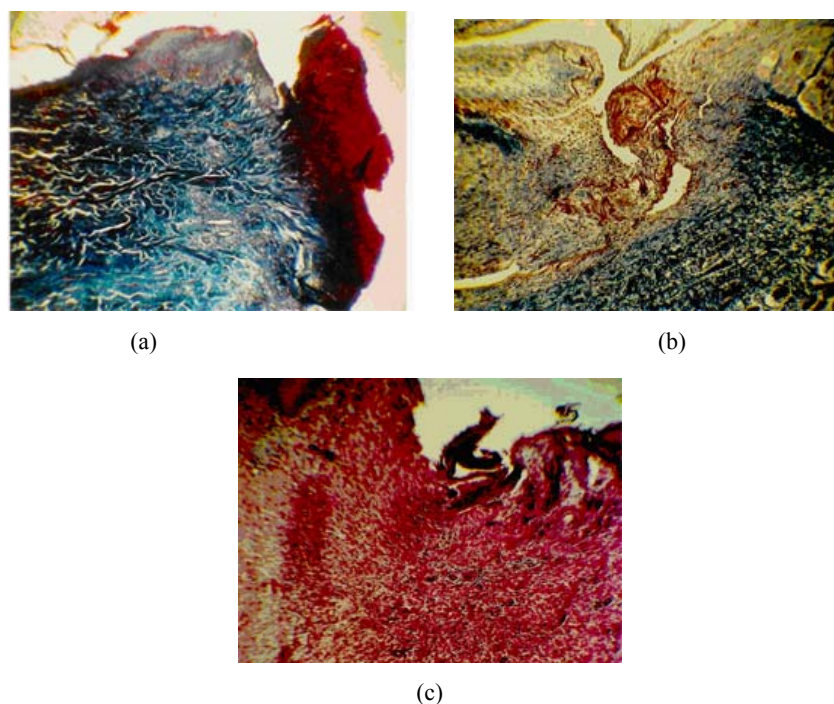


Fig. 2 – Control group (animal 1) - surgical wound in the 7th postoperative day; papillary dermis (trichromic coloration 10×); b) hiperkeratosis and lymphohistiocytic infiltration of the papillary dermis (trichromic coloration 10×); c) dermic scar and vascular network and no epithelization (HE coloration).

Blood chemistry has shown variations within normal range for both the experimental group and the control one. Glucose, blood nonproteic nitrogen and the liver enzymes have shown normal results for the species (Table 1).

Table 1

Average results for some biochemical blood determinations

Parameters	Normal values	Treatment duration of LLLT (days)									
		1		2		3		4		5	
		EG ^{a)}	CG ^{b)}	EG	CG	EG	CG	EG	CG	EG	CG
Glucose (mg/dl)	112-160	83± 0.8809	93.95± 0.8739	118.4± 0.6557	68.2± 0.7594	136± 0.4235	75.6± 0.6342	67.85± 0.4977	70.4± 0.7489	117.8± 0.5966	143.5± 0.4197
Urea (mg/dl)	< 54	50.98± 0.6893	54.7± 0.5835	24.64± 0.6723	30.5± 0.4279	22.34± 0.7257	47.3± 0.3943	36.95± 0.5020	32.35± 0.3766	46.62± 0.2914	35.2± 0.5492
ASAT (GOT)	76 - 129	81± 0.5941	179± 0.3877	41.84± 0.7743	47.6± 0.6835	47.6± 0.7235	24.14± 0.8826	31.8± 0.5972	35.4± 0.6026	127± 0.3324	76.5± 0.5459
ALAT (GPT)	75-119	29.95± 0.7265	43.9± 0.6211	55.4± 0.6868	49± 0.5707	49± 0.5798	45.7± 0.6153	40.87± 0.5542	75.05± 0.6185	71.9± 0.5427	70.05± 0.6609
GGT	0.15-18	5± 0.1993	5± 0.2571	14.94± 0.1103	18.4± 0.1729	18.4± 0.2458	18.3± 0.2541	8.25± 0.1927	15.05± 0.1699	7.21± 0.2105	20± 0.2917

a) EG - experimental group

b) CG - control group

The alkaline phosphatase shows a different dynamic. In the experimental group this enzyme showed higher levels than the ones in the control group (Fig. 3). These values sometimes above normal range can be the markers of the regeneration process in surgical wounds [20].

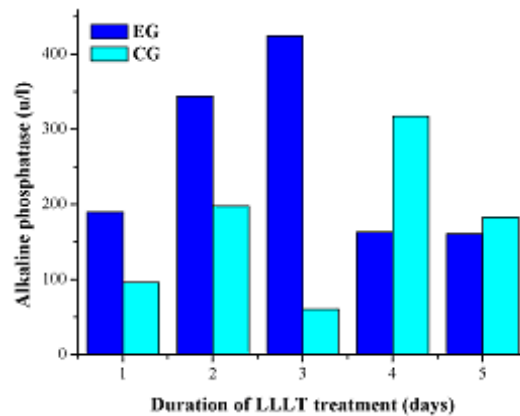


Fig. 3 – Average values of the alkaline phosphatase during the healing phase of the surgical wounds

This phenomenon is explained by the higher oxygen and nutrient necessities during the healing phase [21]. During the experiment the level of the alkaline phosphatase is high.

The hematologic exams have watched the red blood cell count and other erythrocytic parameters (VEM, HEM, Hb and Ht) in the experimental and the control groups. In the group that was exposed to laser radiation, these parameters showed slightly higher values compared to the control group. This dynamic can correlate with the healing process, being a part of the whole regenerative reaction [22]. The erythrocyte count has shown high levels starting the 3rd postoperative day, levels that maintain during the whole experiment, though not above the normal range (Fig. 4a). This fact is generated by the higher oxygen necessity during the tissular regeneration as a reaction to the treatment. Haemoglobine levels are high in the second and third postoperative days (Fig. 4b) as well as the average erythrocyte haemoglobine (Fig. 4c).

A specific pattern shows the leucocyte count, which shows above average levels. In the control group this parameter is constantly high, more than 8000/ μ l starting the first postoperative days and in the experimental group there is a constant increase of this count as we approach the 6th, 7th postoperative days (Fig. 4d). The high leucocyte levels are both generated by the lymphocytes and monocytes, both implicated in defense processes locally and generally. Monocytes are participating in phagocytosis in interleukine and lymphocyte growth factor synthesis [23].

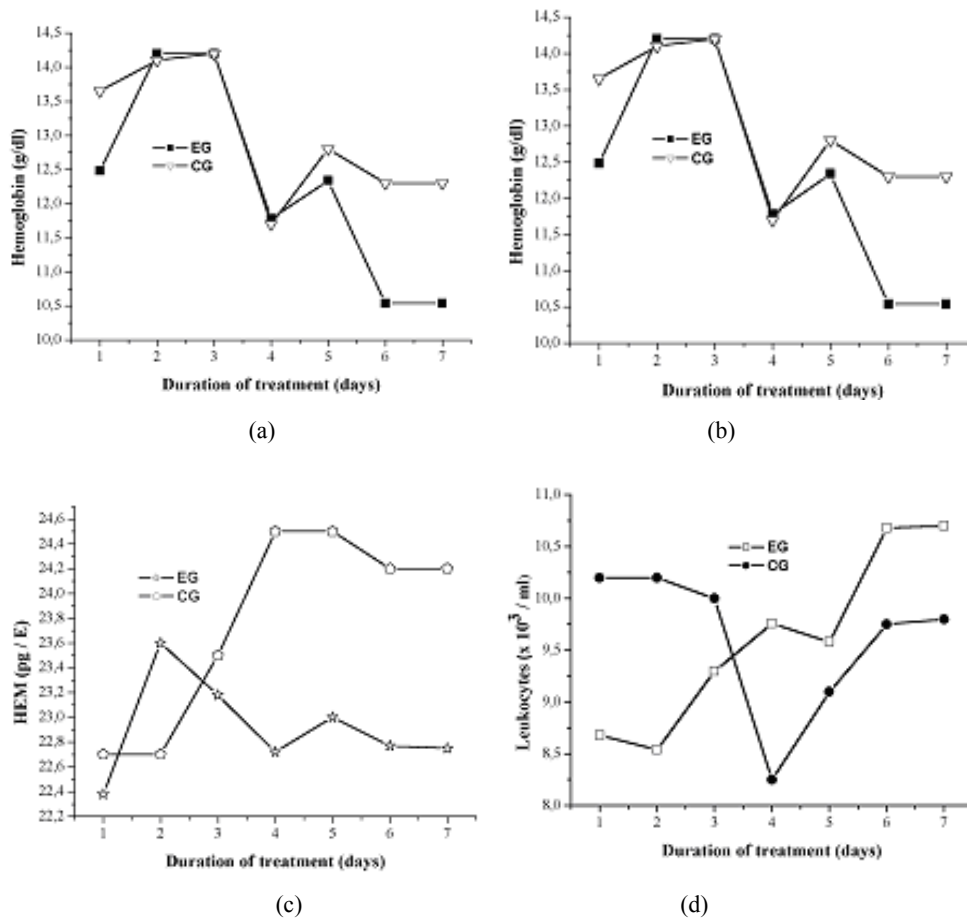


Fig. 4 – The dynamics of the main hematologic parameters during the treatment of the aseptic surgical wounds; a) red blood cell count; b) haemoglobine; c) average erythrocytic haemoglobine; d) leukocyte count.

A specific pattern shows the leukocyte count, which shows above average levels. In the control group this parameter is constantly high, more than $8,000/\mu l$ starting the first postoperative days and in the experimental group there is a constant increase of this count as we approach the 6th, 7th postoperative days (Fig. 4d). The high leukocyte levels are both generated by the lymphocytes and monocytes, both implicated in defense processes locally and generally. Monocytes are participating in phagocytosis in interleukin and lymphocyte growth factor synthesis [23].

The histological examination of blood cells has shown:

- The erythrocytes show normal aspects in most of the cases. In one case microcytosis and acanthocytosis were found in the first 2 days after the

irradiation started, but everything returned to normal after 48 hours of treatment.

- The leukocytes showed some changes like lymphocytic atypias in the last days of treatment. Lymphoblast count raise can be associated with intense tissue regeneration in the final stages of the treatment when local scarring and epithelization processes are accelerated.

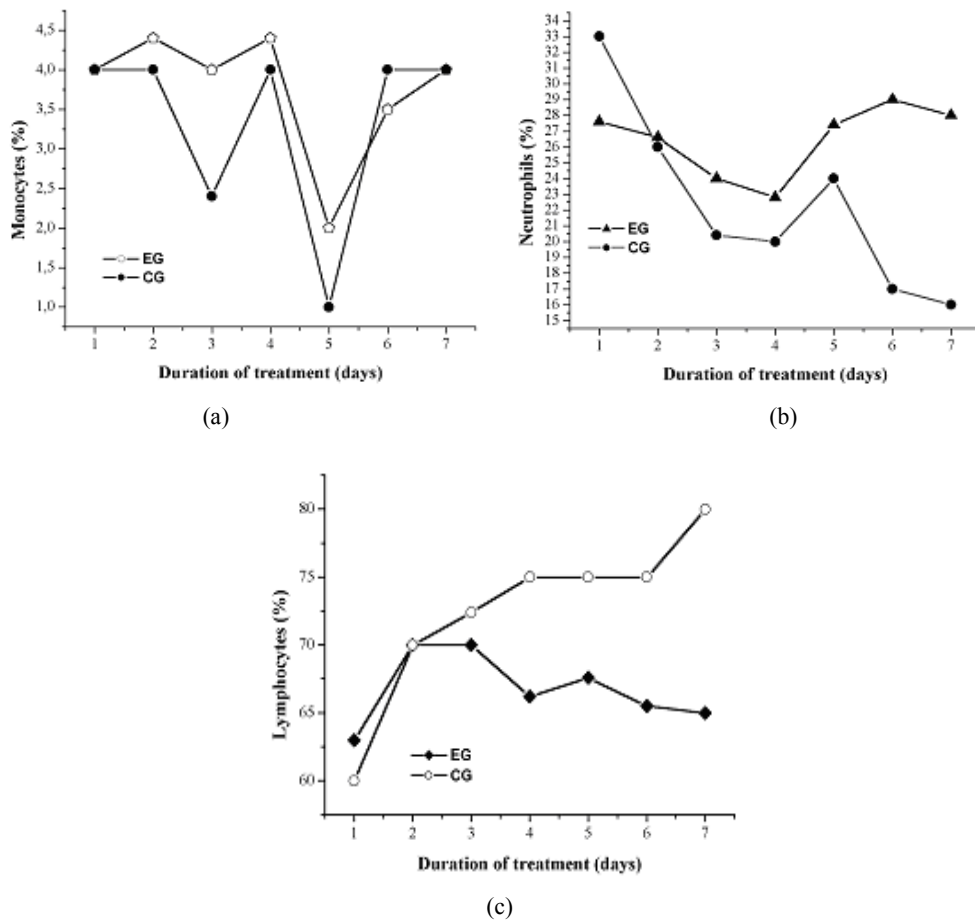


Fig. 5 – The white cell count during laser therapy of aseptic surgical wounds: a) monocytes; b) neutrophils; c) lymphocytes.

On average the monocyte count is high both in the experimental and the control group. The monocytes are as high as 2 to 4.4 % from all the leukocyte population, the normal values for the species being around 1.6% (Fig. 5a). The monocytosis seen under laser radiation can be a sign of enhanced immunological processes as long as these cells take part in local and general, immune and

nonspecific defense mechanisms [24]. Neutrophils, which play a major role in host defense via the phagocytosis and destruction of pathogens during acute inflammation [25] show higher counts in the experimental group than in the controls which suggests an increase in phagocytic process in the wound in the last 4 days of treatment (Fig. 5b). Lymphocytes, which have complex roles both in regeneration and immune defense, show higher levels than the control group during the whole treatment period (Fig. 5c).

It can be stated that all the cells participating in immune system reaction and in tissue regeneration showed higher levels in the animals treated with low energy laser compared with the control group, demonstrating the stimulative effect of this type of radiation.

4. CONCLUSIONS

Treating the surgical wounds with low level energy laser radiation proved to be useful and efficient because the primary healing was stimulated, the process ending in the 10th postoperative day. The biochemical blood examination showed normal enzyme levels in both groups, with the exception of alkaline phosphatase, which showed increases of 100 to 200 % above physiological limits in the experimental group, values 2 or 3 times higher than the ones measured in the control group.

The erythrocytic indices showed higher levels of erythrocyte counts and average erythrocyte volume in the experimental group compared to the controls which suggests a better oxygen input into the tissues as a result of biostimulation. It was also histologically proven that the epithelization and dermis repair are accelerated in the treated group.

The white blood cell count dynamics suggests a stimulation of the immune system and the regenerative processes, reflected in monocytosis (a feature observed in both groups), and in lymphocytosis (which is significant in the treated group).

All these data have shown LLLT to be effective in the treatment of surgical wounds.

REFERENCES

1. A.L. Bertone, *Principles of wound healing*, Vet Clin North Am Equine Pract., **5**, 449–63 (1989a).
2. A.L. Bertone, *Second-intention healing*, Vet Clin North Am Equine Pract., **5**, 539–50 (1989b).
3. Z. Simunovic, A.D. Ivankovich, A. Depolo, *Wound healing of animal and human body sport and traffic accident injuries using low-level laser therapy treatment: a randomized clinical study of seventy-four patients with control group*, J Clin Laser Med Surg., **18**, 67–73 (2000).
4. C. Lucas, L.J. Criens-Poublon, C.T. Cockrell, R.J. R.J. de Haan, *Wound healing in cell studies and animal model experiments by Low Level Laser Therapy; were clinical studies justified? A systematic review*, Lasers Med Sci., **17**, 2, 110–34 (2002).

5. J.T. Hopkins, T.A. McLoda, J.G. Seegmiller, G.D. Baxter, *Low-Level Laser Therapy Facilitates Superficial Wound Healing in Humans: A Triple-Blind, Sham-Controlled Study*, Journal of Athletic Training, **39**, 3, 223–29 (2004).
6. W. Posten, D.A. Wrone, J.S. Dover, K.A. Arndt, S. Silapunt, M. Alam, *Low-level laser therapy for wound healing: Mechanism and efficacy. Dermatol Surg*, **31**, 3, 334–40 (2005).
7. M.R. Jr. Adeir, J.V. Beatriz, C. Luis, *Effects of low-level laser therapy on the progress of wound healing in humans: the contribution of in vitro and in vivo experimental studies*, J Vasc Bras, **6**, 3, 258–66 (2007).
8. J.R. Basford, *Low Intensity Laser Therapy: Still not an established clinical tool*, Lasers Surg Med, **16**, 331–42 (1995).
9. G.D. Baxter, *Therapeutic laser -Therapy and practice*, 3-rd ed., New York, Churchill Livingstone, 1997.
10. J. Tuner, L. Hode, *It's all in the parameters: a critical analysis of some well-known negative studies on low-level laser therapy*, J Clin Laser Med Surg, **6**, 245–48 (1998).
11. D. Bisht, R. Mehrotra, P.A. Singh, S.C. Atri, A. Kumar, *Effect of helium-neon laser on wound healing*, Indian J Exp Biol, **37**, 2, 187–89 (1999).
12. H.T. Whelan, R.L. Smits, E.V. Buchman, N.T. Whelan, S.C. Turner, D.A. Margolis, V. Cevenini, V. Stinson, R. Ignatius, T. Martin, J. Cwiklinski, A.F. Philippi, W.R. Graf, B. Hodgson, L. Gould, M. Kane, G. Chen, J. Caviness, *Effect of NASA light-emitting diode irradiation on wound healing*, J Clin Laser Med Surg, **19**, 6, 305–14 (2001).
13. P. Gal, B. Vidinský, T. Toporcer, M. Mokry, S. Mozeš, F. Longauer, J. Sabo, *Histological Assessment of the Effect of Laser Irradiation on Skin Wound Healing in Rats*, Photomedicine and Laser Surgery, **24**, 4, 480–88 (2006).
14. N. Hourelid, H. Abrahamse, *In vitro exposure of wounded diabetic fibroblast cells to a helium-neon laser at 5 an 16 J/cm²*, Photomed Laser Surg, **25**, 78–84 (2007).
15. L.A. Lopes, J. Rigau, R.A. Zângaro, J. Guidugli-Neto, M.M.M. Jaeger, *Comparison of the low level laser therapy effects on cultured human gingival fibroblasts proliferation using different irradiance and some fluence*, Lasers Surg Med, **29**, 2, 179–84 (2001).
16. T.M. Mendez, A. Pinheiro, M. Pacheco, P. Nascimento, L. Ramalho, *Dose and wavelength of laser light have influence on the repair of cutaneous wounds*, J Clin Laser Med Surg, **22**, 1, 19–25 (2004).
17. F.A.H. Al-Watban, X.Y. Zhang, *The comparison of effects between pulsed and CW lasers on wound healing*, J Clin Laser Med Surg, **22**, 1, 15–8 (2004).
18. D. Hawkins, H. Abrahamse, *Effect of multiple exposure of low level laser therapy on the cellular responses of wounded human skin fibroblasts*, Photomed Laser Surg, **24**, 705–14 (2006).
19. A. Franek, P. Krol, M. Kucharzewski, *Does low output laser stimulation enhance the healing of crural ulceration? Some critical remarks*, Med Eng Phys, **24**, 9, 607–15 (2002).
20. G. Aplaslan, T. Nakajima, Y. Takano, *Extracellular alkaline phosphatase activity as a possible marker for wound healing: a preliminary report*. Oral Mazillofac Surg, **55**, 1, 56–62 (1997).
21. F.A.H. Al-Watban, B.L. Andres, X.Y. Zhang, *Wound Healing Efficacy of Hene Laser (632.8 nm) and Pharmacological Treatments in Normal Rats*, Lasers Life Sci., 1–10 (2000).
22. M.B. Witte, A. Barbu, *General principles of wound healing*, Surg Clin North Am., **77**, 509–28 (1997).
23. D.H. Cormack, *Histologia*, 9 ed., in Guanabara Koogan editor, Rio de Janeiro, 1991.
24. M.G. Bouma, W.A. Buurman, F.A. van den Wildenberg, *Low energy laser irradiation fails to modulate the inflammatory function of human monocytes and endothelial cells*, Lasers Surg Med, **19**, 2, 207–15 (1996).
25. T.S. Chen, E. Koutsilier, P. Kruzik, W.D. Rausch, *Intracellular calcium and pH sensitive parameters of toxicity in neural cell culture*, ALTEX, **11**, 4, 216–191994.